

**PATIENT**

Kira Bell

**SPECIES**

Feline

**BREED**

Siberian

**SEX**

Female

**AGE**

1.7 years

**WEIGHT**

11lbs

**INTERPRETED BY**

Maggie Machen Lamy,  
DVM, DACVIM  
(Cardiology)

**IMAGING PERFORMED BY**

Alex McFeely, DVM

**HOSPITAL NAME**

Centre AH

**REFERRING VET**

Dr. Alex McFeely

**INVOICE**

47836

**DATE**

5/13/26

**PRESENTING CLINICAL SIGNS**

History: Previously diagnosed with HCM 6 months ago (Antech). Asymptomatic. BP: 129-152mmHg. On Plavix; compliance is becoming an issue due to pill form.

**ECHOCARDIOGRAM FINDINGS**

2D, m-mode, color flow and doppler imaging is available. The left ventricular wall is irregular with borderline hypertrophy overall. There is a diffusely hyperechoic endocardium consistent with fibrosis. The endocardium also appears remodeled. Mild papillary muscle hypertrophy. The left atrium is slightly dilated and bulbous in appearance. The right atrium is normal in size. The right ventricle appears normal. The mitral valve is normal in structure and mobility. Trace MR. No TR. The LVOT velocity is not assessed; however, no obvious obstruction is seen on 2D imaging. Blood flow through the RVOT is normal in velocity. No pericardial effusion. No obvious cardiac tumors identified.

**CARDIAC CHART**

FELINE CARDIAC PARAMETERS	BODY WEIGHT (kg)	HR (BPM)	IVSd (cm) (Moise, Pipers)	LVIDd (cm) (Moise, Pipers)	LVWd (cm) (Moise, Pipers)	FS (%)	EF (%)
NORMAL PARAMETER	-----	150-240	0.35-0.55	<2 (mean 1.5)	3.5-0.55	35-67	80-100
PATIENT	5.0	NM	0.52	1.3	0.50	47	90
FELINE CARDIAC PARAMETERS	LA/AO (Boon)	LA/AO HEART BASE (Swe) (Abbott)	LA 2D short axis Base view (cm) (Abbott)		LVOT VEL (m/s)	RVOT VEL (m/s)	E max (m/s)
NORMAL	<1.5	<1.3	<1.2		<1.6	<1.3	<0.9
PATIENT	NM	1.5	1.3		NM	0.8	NM

*\*Note: All measurements based upon multi-modal images and methods. An average value is reported.*  
Adapted from June Boon, Veterinary Echocardiography, 1998  
Abbott J & MacLean H JVIM 2006;20: 111-119, Moise et al. Am J Vet Res 47:1476, 1986. Pipers et al. Am J Vet Res 40:882, 1979.

**INTERPRETATION OF THE FINDINGS & FURTHER RECOMMENDATIONS**

Borderline septal LV hypertrophy is present, in addition to slight left atrial enlargement. This may be indicative of early hypertrophic disease or may simply represent a normal variant. Regardless, what is seen here is minimal with only slight LA enlargement. There may be risk for progression going forward in this senior cat and serial echocardiography is recommended. No additional issues are seen.

Given these findings, no medications are indicated. Plavix is typically utilized once moderate or worse atrial enlargement is seen, which is not identified here. These findings are minimal overall, and Felcyn is not recommended in this case. No further comment or comparison can be made without a prior echo report.



## PATIENT

Prognosis is guarded prior to assessing for progression.

Kira Bell

## SPECIES

Feline

## BREED

Siberian

## SEX

Female

## AGE

1.7 years

## WEIGHT

11lbs

## INTERPRETED BY

Maggie Machen Lamy,  
DVM, DACVIM  
(Cardiology)

## IMAGING PERFORMED BY

Alex McFeely, DVM

## HOSPITAL NAME

Centre AH

## REFERRING VET

Dr. Alex McFeely

## INVOICE

47836

## DATE

5/13/26

Anesthetic risk is considered mild, however judicious IV fluid rates are advised to avoid fluid overload. Additionally, drugs that stimulate heart rate should be avoided unless clinically necessary (glycopyrrolate, atropine). Avoid vasodilators as this may worsen the obstruction. A reasonable protocol includes opioid/benzodiazepine premedication, propofol induction, and isoflurane maintenance. Additionally, steroids should be used with caution in cats with any degree of LA enlargement, as risk for complication follows this measurement. An inhaled version may be better tolerated. Monitoring of RR/RE is recommended, particularly during the initiation phase.

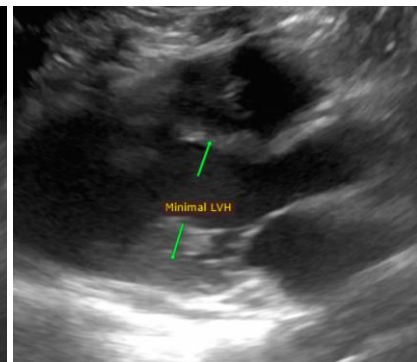
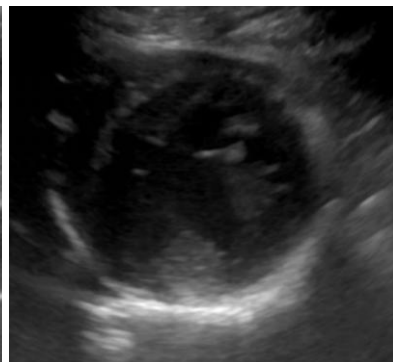
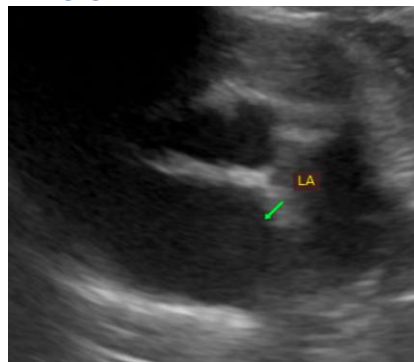
Monitor for any development of clinical signs, including labored breathing or signs of a blood clot (paralysis, neurologic change).

## PLAN

Reasonable to withhold Plavix prior to further evaluation. Monitor BP/T4 every 6 months.

A recheck echocardiogram is recommended in 6-12 months to screen for any evidence of progression, sooner if clinical issues arise.

## IMAGES



**The information and recommendations provided are based on the images presented by the referring veterinarian. No evaluation can be communicated regarding pathology that was not visible in the image/video clips provided.**

Thank you for this referral. This report was generated using transcription software, and minor dictation errors may be present. If the clinical or image interpretation does not parallel your findings or if I can be of any further assistance, please contact me.

**Maggie Machen Lamy, DVM**

**Diplomate of the American College of Veterinary Internal Medicine (Cardiology)**

info@sonopath.com